

## **Trichinella Spiralis Infestation Complicating Open Reduction and Internal Fixation for Closed Fracture Femur.**

T Beyeza<sup>1</sup>, M Odida<sup>2</sup>, J Okello<sup>1</sup>

<sup>1</sup>Department of Orthopaedics, <sup>2</sup>Department of Pathology, Mulago Hospital.

*Correspondence to:* Dr. J Okello, Email: justinokello2002@yahoo.co.uk

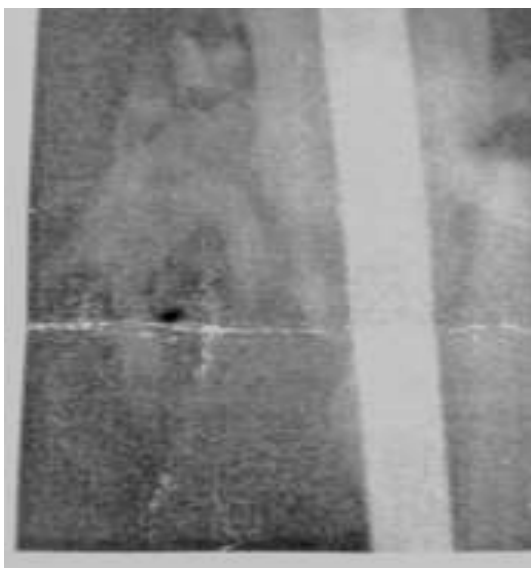
**Trichinella Spiralis infestation complicating internally fixed fracture has not been reported. We report a case of trichinella spiralis infestation complicating a closed fracture of femur that was managed by open reduction and internal fixation using Kuntcher nail resulting into non-union.**

### **Case Report**

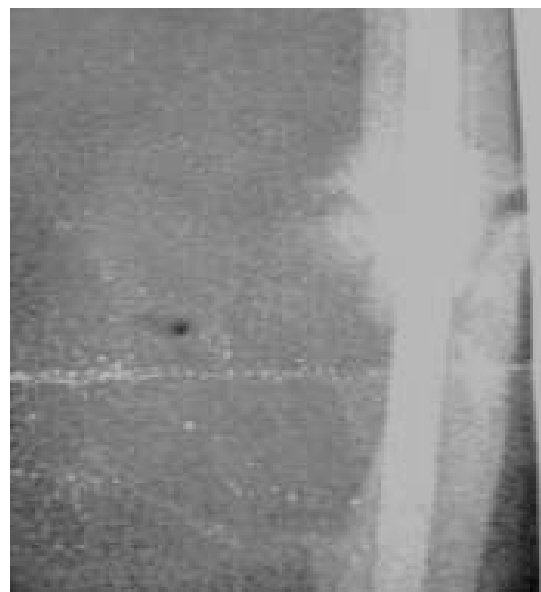
A 34year old male was admitted to our unit with a closed fracture of his right femur following road traffic accident. x-ray taken showed fracture of the proximal third of the right femur. He was treated operatively using intramedullary Kuntcher nail on the 10<sup>th</sup> day after the injury and he recovered well postoperatively and was discharged ambulating on axillary crutches.

During the follow up, the patient was found to be having a painful swelling on the medial side of the operated site of his thigh. At 9 months after surgery, check x-ray was taken and it showed a cystic soft tissue mass with a well circumscribed calcified capsule around the fracture site and a non-union with associated bone loss on the medial aspect leaving the nail exposed (**Figs 1 and 2**). Ultrasound scan of the swelling showed a well circumscribed mass but it was not conclusive and full blood count was normal.

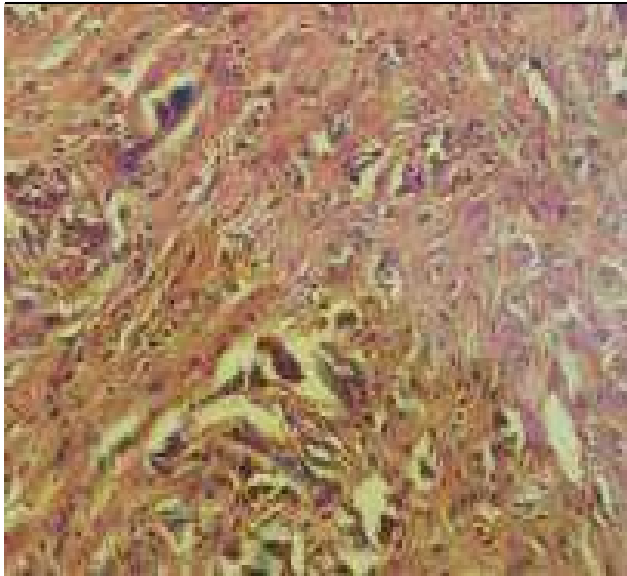
In view of the non union and the mass, a decision to repeat the surgery was made. At surgery, a well encapsulated mass measuring about 8cm x 6cm with a thick wall was found. Beneath it was a thick elongated fibrous tissue with thick greenish fluid in between the layers. The mass was excised and the surrounding soft tissue and bone was debrided followed by plating with a broad dynamic compression plate (DCP).



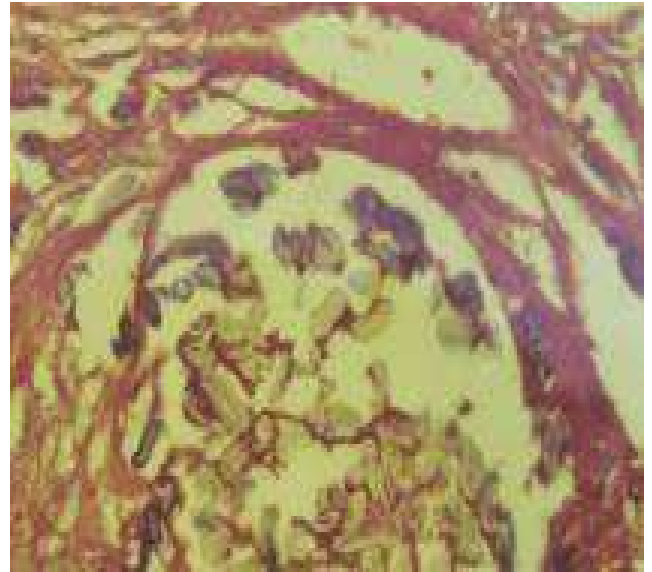**Figure 1.**



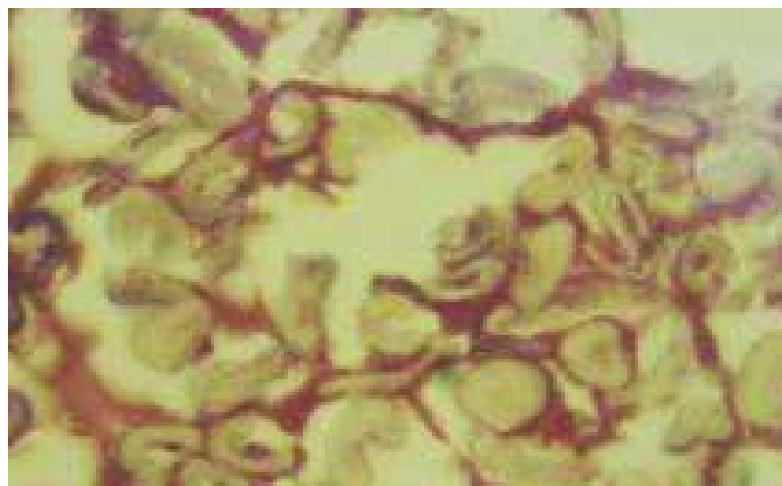
**Figure 2.**



**Figure 3**



**Figure 4**



**Figure 5**

Three months after surgery, check x-ray taken showed failure of the DCP. Another operation was done to remove the plate and replaced it with intra-medullary Russell Taylor nail and the fracture eventually united.

Histological examination of the tissue from the mass was carried out and revealed cyst like spaces containing larvae of trichinella spiralis and occasional giant cells as shown in **Figures 3, 4 and 5.**

### **Discussion**

Trichinosis is a self limiting infestation of man usually following consumption of uncooked or undercooked Pork contaminated with infective larvae or small adult trichinella spirallis. Most cases are subclinical. The symptoms can be local or systemic. The local symptoms are due to the presence of the adult worms in the intestinal tract during the first week of infestation and this include; diarrhoea, vomiting and nausea. Symptoms associated with systemic invasion include; myositis, swelling, fever, pain, and weakness which occur during the second week of

infestation<sup>1, 2, 3</sup> and it causes long lasting sequel<sup>4</sup>. In children, it has a benign course and milder clinical picture<sup>5</sup>

Involvement of the skeletal muscles is common and the muscle fibre becomes oedematous, loose their cross striation, undergoes basophilic degeneration and their nuclei proliferate. The typical worm coiled in a cyst wall derived from the host cells with a surrounding lymphocytic and eosinophilic infiltration within the muscle fibres. Trichinosis complicating fracture has not been reported, however trichinosis associated with other disease condition has been documented<sup>1, 6, 7, 8</sup>.

Trichinosis affects calcium metabolism leading to reduction in weight and tensile stress resistance of bone<sup>9</sup>. The calcium reduction is due to is due to the active cyst calcification. The non union in this case could have resulted from the local destruction of soft tissue by the parasite leading to ischemia and its effect on calcium metabolism. Diagnosis is made on muscle biopsy which may show trichinella spiralis coiled within the muscle in host nurse cells surrounded by a capsule. Inflammatory cells at the site include; monocyte, plasma cells, eosinophils and T-Lymphocytes<sup>10</sup>.

## References

1. Cecil textbook of medicine; Beeson McDermoh Wyngaaden, pp630-31.
2. Principles and practice of infectious diseases; Mandell Douglas, Benett pp2165-66.
3. Wand M, Hyman D, trichinosis from bear meat: clinical and laboratory feature JAMA 220- 245.1972.
4. Feldemeir H et al: Sequella after infection with trichinella spiralis;A prospective cohort study Wien Klin Woschensch,1991;103(4): 111-6.
5. OzdemirD.Ozkan H. et al, Acute trichinosis in children compared with adult; Parasitology- 2005 sept; (p13): 373-81.
6. Bruce R.A. Trichinosis associated with oral squamous cell carcinoma; report of three cases. J Oral Surg. 1975 Feb: 33(2) ; 136-41.
7. Kristek J et al. Trichinella spiralis and breast carcinoma- a case report Coll Antropol 2005dec; 29(2) 775-7.
8. Harnandez M. Ramost Matinez Diaz Gastallin;Chronic Endometrioiosis caused by Trichinella spiralis. Report of a case; Ginnecol Obstet max 1995 mar;109-11.
9. Harley J.P. Ross B S Osteolysis in Trichinella Spiralis infected vs. non infected, Camp Biochem physiolo A. 1982;72(1) 111-4.
10. Taratuto A, Ventuviello SM, Trichinosis Braib Pathol, 1979 Jan; 7(1): 663-72.